Clinical Practice Guidelines

EASL JOURNAL OF HEPATOLOGY

EASL Clinical Practice Guidelines on the management of benign liver tumours☆

European Association for the Study of the Liver (EASL)*

Introduction

Benign liver tumours are a heterogeneous group of lesions with different cellular origins, as summarized by an international panel of experts sponsored by the World Congress of Gastroenterology in 1994 [1]. These lesions are frequently found incidentally as a consequence of the widespread use of imaging tests and often have a benign course. Some of these lesions are of greater clinical relevance than others, and the aim of these recommendations is to provide a contemporary aid for the practical diagnosis and management of the more common benign tumours. These include haemangiomas, focal nodular hyperplasia (FNH) and hepatocellular adenoma (HCA).

The evidence and recommendations in these guidelines have been graded according to the grading of the recommendations assessment development and evaluation (GRADE) system [2]. The strength of recommendations reflects the quality of underlying evidence. The GRADE system offers two grades of recommendation: strong (1) or weak (2) (Table 1). The clinical practice guidelines thus consider the quality of evidence: the higher the quality of evidence, the more likely a strong recommendation is warranted; the greater the variability in values and preferences, or the greater the uncertainty, the more likely a weaker recommendation is warranted.

Basic management of a 'liver nodule'

Liver nodules are often identified initially on an abdominal ultrasound scan (US). An US may be performed to investigate a symptom, such as abdominal pain or weight loss, a sign such as hepatomegaly, a finding such as abnormal liver function tests, or possibly an unrelated condition (e.g., a urinary tract infection). Current patient history should cover the presenting complaint and past medical history and should determine whether the individual has any condition associated with the development of liver lesions. These may include a previous cancer or constitutional symptoms (anorexia, weight loss, asthenia) or fever which may point to malignancy or an infection. A history of foreign travel or dysentery may be important if an amoebic abscess is suspected. A systemic enquiry should explore if there are symptoms or signs to support a primary malignancy elsewhere, such as altered bowel habit, a breast lump or a skin lesion. A medication history is always important, but in the context of a 'liver lump' should specifically establish use of oral contraceptive pills (OCPs). In addition, direct questioning should identify any risk factors for chronic liver disease or cancer. These include a known history of viral hepatitis or cirrhosis, history of transfusion, tattoos, intravenous drug abuse, family history of liver disease or liver tumour, alcohol excess, smoking, features of the metabolic syndrome (obesity, type 2 diabetes mellitus, hypertension, cardiovascular disease) and a drug history, which may identify those such as methotrexate, tamoxifen or androgens.

Following examination and baseline investigations, which should aim to exclude underlying chronic liver disease, contrast enhanced (CE) imaging for tumour characterization is indicated, with options including CE ultrasound (CEUS), computer tomography (CT) and magnetic resonance imaging (MRI). If cancer is suspected, a CT scan would provide a rapid assessment and is widely available. MRI may take longer and induces more anxiety in individuals with claustrophobia, but unlike CT, does not use ionizing radiation. Based on the water content and magnetic properties, MRI provides a more detailed assessment of tissues. MRI is therefore preferable as a first line assessment when a benign lesion is suspected, especially in a young individual. In association with an unremarkable baseline history, examination and blood tests, imaging is frequently sufficient to establish a diagnosis of a benign liver tumour and inform subsequent management decisions. It is important, however, not to misdiagnose a malignancy. If there is significant doubt, biopsy or resection may be appropriate. However, these are invasive procedures associated with risk and should only be pursued after consideration by an experienced multidisciplinary team (MDT).

Received 5 April 2016; accepted 5 April 2016

☆ *Clinical Practice Guideline Panel:* Massimo Colombo (Chairman), Alejandro Forner, Jan Ijzermans, Valérie Paradis, Helen Reeves, Valérie Vilgrain, Jessica Zucman-Rossi.

* Corresponding author. Address: European Association for the Study of the Liver (EASL), The EASL Building – Home of European Hepatology, 7 rue Daubin, CH 1203 Geneva, Switzerland. Tel.: +41 (0) 22 807 03 60; fax: +41 (0) 22 328 07 24.
E-mail address: easloffice@easloffice.eu.

Please cite this article in press as: EASL Clinical Practice Guidelines on the management of benign liver tumours. J Hepatol (2016), http://dx.doi.org/10.1016/j.jhep.2016.04.001

Clinical Practice Guidelines

The benign liver tumour multidisciplinary team

The team should be one with expertise in the management of benign liver lesions and should include a hepatologist, a hepatobiliary surgeon, diagnostic and interventional radiologists and a pathologist. Each member of the team must hold specific and relevant training, expertise and experience relevant to the management of benign liver lesions. The team should be one with the skills required not only to appropriately manage these patients, but also manage the rare but known complications of diagnostic or therapeutic interventions.

For each of the common benign lesions, this guideline will include a summary of epidemiological data, pathology, pathophysiology and natural progression, radiological features and diagnostic criteria, as well as recommendations for management.

Hepatic haemangiomas

Epidemiology

Hepatic haemangiomas are the most common primary liver tumours. Haemangiomas are present in 0.4–20% of the general population, and are typically discovered incidentally during evaluation of non-specific abdominal complaints [3–5]. The prevalence of haemangiomas is generally estimated to be around 5% in imaging series [6], but has been reported as high as 20% in autopsy series [4,7]. Haemangioma can be diagnosed in all age groups but are more frequently diagnosed in women between 30–50 years. Reported female to male gender ratios are variable, ranging from as low as 1.2:1 and as high as 6:1 [7]. Hepatic haemangiomas are frequently small (<4 cm) and solitary, although they can reach 20 cm in diameter. Even when they are large, most patients are asymptomatic [4,7].

Pathophysiology, natural course and pathology

Hepatic haemangiomas belong to the group of non-epithelial lesions. They are very commonly observed in surgical specimen resected for other reasons. Haemangiomas measuring 10 cm or more, referred to as "giant haemangiomas", may be symptomatic, including pain and features of an inflammatory reaction syndrome and coagulopathy named Kasabach-Merritt syndrome (KMS). The pathogenesis of haemangioma is an ill understood, possibly congenital disorder with possible hormonal dependence [8,9]. KMS refers to any vascular lesion associated with thrombocytopenia and a consumptive coagulopathy and purpura. Although KMS might complicate any haemangioma, as has been classically described, epidemiological data suggest that it is more likely to be associated with large haemangiomas (>5 cm) [10,11]. In particular, the two specific entities kaposiform haemangioentheliomas and tufted angiomas are highly associated [11]. KMS is related to platelet trapping, activation and consumption within the abnormal vascular structure, with the relationship between platelets and endothelial cells at the core of its pathogenesis. In these vascular lesions, breaches in endothelial integrity occur, leading to exposure to subendothelial collagen and tissue factors, and culminating in platelet aggregation and activation of the coagulation cascade [10,11].

Macroscopic examination of haemangiomas demonstrates well-delineated, flat lesions of red-blue colour that may partially collapse on sectioning. Sizes range from <3 cm ("capillary haemangiomas") to up to 10 cm ("cavernous or giant haemangiomas"). Irregular borders and presence of multiple haemangioma-like vessels in the liver parenchyma adjacent to the vascular mass have been reported in cavernous haemangioma [12]. Some degrees of fibrosis, calcification and thrombosis may be observed, most commonly in larger lesions. Microscopically, haemangiomas are made of cavernous vascular spaces lined by a flattened endothelium over which are fibrous septa of various widths. Small haemangiomas may become entirely fibrous, appearing as a solitary fibrous nodule and reported as an hepatic sclerosed haemangioma. These can occasionally be misdiagnosed as a malignant fibrous tumour [13].

Table 1. Grading evidence and recommendations (adapted from GRADE system).

Grade evidence	
I	Randomised, controlled trials
II-1	Controlled trials without randomisation
II-2	Cohort or case-control analytical studies
II-3	Multiple time series, dramatic uncontrolled experiments
III	Opinions of respected authorities, descriptive epidemiology

Grade recommendation	
1	Strong recommendation: Factors influencing the strength of the recommendation included the quality of the evidence, presumed patient-important outcomes, and cost
2	Weaker recommendation: Variability in preferences and values, or more uncertainty: more likely a weak recommendation is warranted. Recommendation is made with less certainty: higher cost or resource consumption

Haemangioma imaging and diagnosis

Upon US, the classic appearance of an haemangioma is that of a homogenous hyperechoic mass, measuring less than 3 cm in diameter with acoustic enhancement and sharp margins. CE examinations (CEUS, CT or MRI) (Fig. 1) are required when US is atypical. They show peripheral and globular enhancement of the lesion followed by a central enhancement on delayed phases [14]. MRI is the key imaging modality in liver haemangiomas and also shows typical findings on pre-contrast imaging (hypointense on T1-weighted sequences and strongly hyperintense on heavily T2-weighted sequences) [15–17]. On diffusion-weighted MR sequences, where the b-value reflects the strength and timing of the gradients used to generate diffusion-weighted images, the signal of a haemangioma drops with increasing b-values. Consequently the apparent diffusion co-efficient (ADC) value is high. Haemangiomas, especially those with high-flow, might show atypical features using gadoxetic acid (hepatobiliary MR contrast agents) – with relatively low signal intensity relative to the surrounding normal liver parenchyma during the equilibrium (3 min delay) phase. This pseudo washout can mimic hypervascular hepatic tumours. However, they can be diagnosed by observing very strong signal intensity on T2-weighted imaging and enhancement on arterial phase-dominant imaging [18].

Please cite this article in press as: EASL Clinical Practice Guidelines on the management of benign liver tumours. J Hepatol (2016), http://dx.doi.org/10.1016/j.jhep.2016.04.001

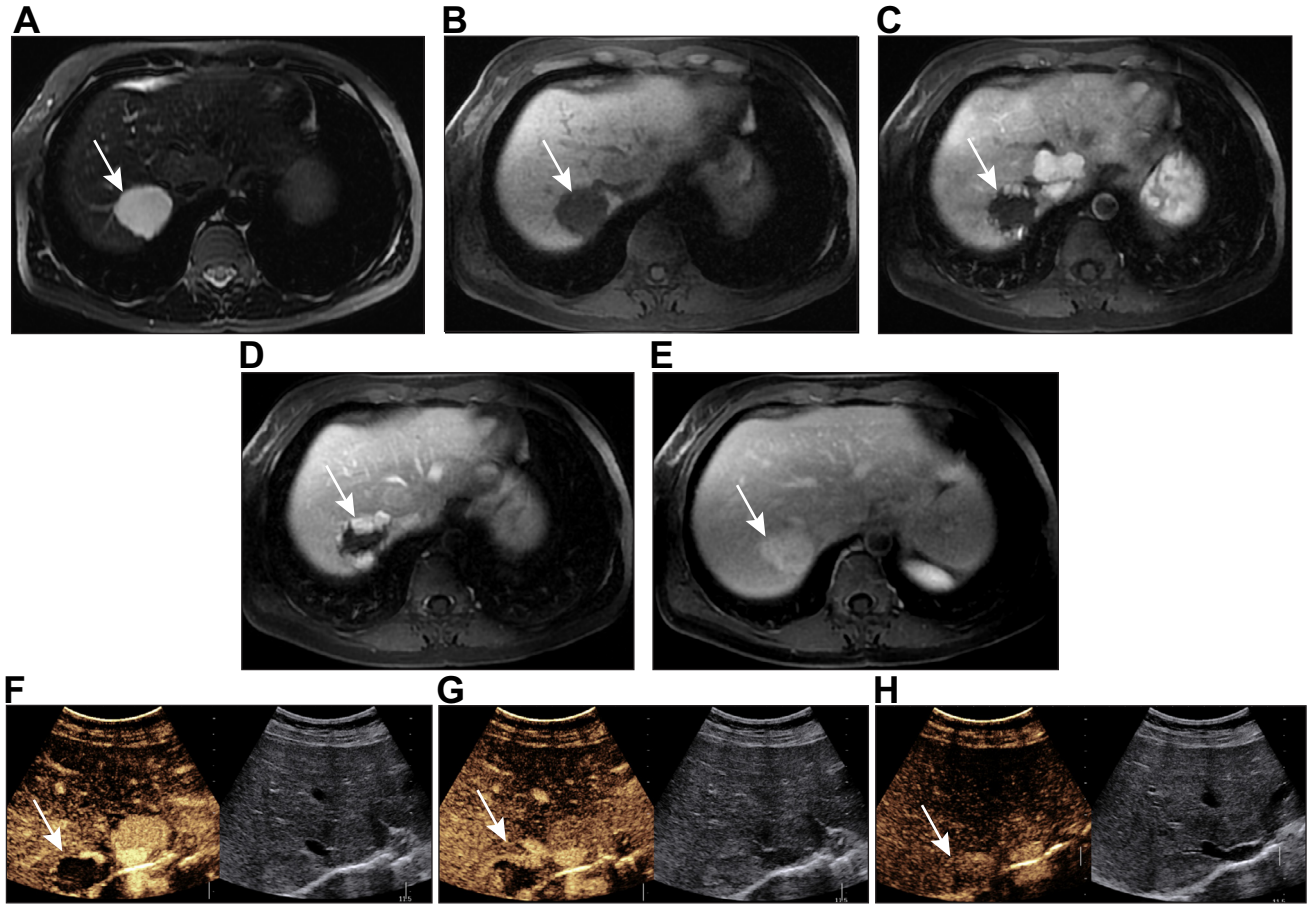

Fig. 1. A typical hemangioma adjacent to FNH on MRI and CEUS. (A and B) The lesion (haemangioma white arrow) is strongly hyperintense on T2 and hypointense on T1. (C–E) On contrast-enhanced images, the lesion shows peripheral and discontinuous enhancement followed by complete fill-in on delayed phase imaging. (F–H) The same enhancement is seen on CEUS. Note that the hemangioma is adjacent to a FNH that does not contain a central element.

The two most common imaging atypias correspond to rapidly filling haemangiomas and giant haemangiomas. Both types of heamangioma are easily diagnosed on MRI [19–21]. The diagnosis of rapidly filling haemangioma is based on strong hyper intensity on T2-weighted images, the enhancement concomitant with that of arterial structures, and the persistent enhancement on delayed phase imaging. Giant haemangiomas may show central heterogeneity related to thrombosis or fibrosis. Acute thrombosis can be diagnosed when haemangioma appear hyperattenuated on unenhanced CT and hyperintense on T1-weighted MRI. The peripheral part of large haemangiomas shows usually classical findings (strong hyperintensity on T2- and globular enhancement). Other atypical haemangiomas are very uncommon and include those that have very slow filling and calcified or hyalinized haemangiomas (also called sclerosing haemangiomas). Occasionally haemangiomas are cystic, pedunculated, have a fluid-fluid level or are associated with capsular retraction. In these very rare situations, imaging, including MRI, is less reliable. MRI has the highest sensitivity and specificity for diagnosing liver haemangiomas with values over 90% [16]. The enhancement patterns of hepatic haemangiomas using gadoxetic acid MR contrast agent can create an imaging pitfall [22].

When the diagnosis cannot be achieved with imaging, percutaneous biopsy may be required. Provided that a cuff of normal hepatic parenchyma is interposed between the capsule and the margin of haemangioma, needle biopsy is not contraindicated and allows a diagnosis with an overall accuracy of 96% [23].

Management

Haemangiomas are most often asymptomatic incidental discoveries that may change in size during long term follow-up [24]. There is no relationship between the size of haemangiomas and complications, with little relationship between symptoms and characteristics of haemangiomas. Whether patients with large lesions, or lesions with mild symptoms, benefit from surgery is debatable [25,26]. No randomized trials are available showing a superior effect of resection as compared to conservative treatment [26]. For the majority of patients, a conservative approach is appropriate. Pregnancy and the use of OCPs are not contraindicated in the presence of stable asymptomatic haemangioma. Incidental reports described the development of KMS during pregnancy in females with liver haemangiomas larger than 5 cm [27].

Symptomatic or giant haemangiomas are not common and affected individuals should be referred to a benign liver tumour MDT. Again, surgical resection is rarely indicated [28], except in the presence of KMS [10,11]. Transcatheter hepatic embolization

Please cite this article in press as: EASL Clinical Practice Guidelines on the management of benign liver tumours. J Hepatol (2016), http://dx.doi.org/10.1016/j.jhep.2016.04.001

can be considered to manage the KMS [10,29,30], as can medical therapy with corticosteroids or vincristine [10,11,31]. Rarely, for complicated, large or extensive unresectable tumours, liver transplantation may be indicated [32,33].

Hepatic haemangioma

- In patients with a normal or healthy liver, a hyperechoic lesion is very likely to be a liver haemangioma. With typical radiology (homogeneous hyperechoic, sharp margin, posterior enhancement, and absence of halo sign) in a lesion less than 3 cm, ultrasound is sufficient to establish the diagnosis (**evidence level II-2, grade of recommendation 1**)
- In oncology patients or those with underlying liver disease, contrast enhanced imaging (CEUS, CT or MRI) is required (**evidence level II-2, grade of recommendation 1**)
- The diagnosis by contrast enhanced imaging is based on a typical vascular profile characterized by peripheral and globular enhancement on arterial phase followed by a central enhancement on delayed phases. MRI provides additional findings such as lesion signal on T1-, T2- weighted sequences, and diffusion imaging (**evidence level II-2, grade of recommendation 1**)
- Due to its benign course, imaging follow-up is not required for typical haemangioma (**evidence level II-2, grade of recommendation 1**)
- Pregnancy and oral contraceptives are not contraindicated (**evidence level III; grade of recommendation 2**)
- Conservative management is appropriate for typical cases (**evidence level II-2, grade of recommendation 1**)
- In the presence of Kasabach-Merrit syndrome, growing lesions or lesions symptomatic by compression - refer to benign liver tumour MDT (**evidence level III, grade of recommendation 1**)

Focal nodular hyperplasia

Epidemiology

FNH accounts for the second most frequent benign tumour of the liver. In unselected autopsy series there is an estimated prevalence of 0.4–3%, although this is reduced to 0.03% considering clinically relevant prevalence [34,35]. There is a marked female preponderance (up to 90%), with the average age at presentation between 35 and 50 years. In most cases FNH is solitary and smaller than 5 cm, although tumours may be larger. FNH are multiple in 20–30% of cases and associated with liver haemangioma in 20% of cases [36–38]. Association of FNH with hepatocellular adenomas (HCA) is less common [39] (although conversely, FNH are relatively common in patients with established adenomas). FNH is thought to represent a proliferative cell response to an aberrant dystrophic artery [40] and may be associated with other conditions characterized by arterial damage, such as hereditary haemorrhagic telangiectasia [41] or previously treated solid tumours in children [42]. Pregnancy and OCPs have not been demonstrated to play a role in development or progression of FNH [43–45].

Pathophysiology, natural course and pathology

FNH is a polyclonal hepatocellular proliferation, considered as a hyperplastic reaction resulting from arterial malformation. This theory is strongly supported by the absence in FNH of somatic mutations described in liver tumorigenesis and the dysregulation of several genes involved in vascular remodeling, such as angiopoietins (ANGPT) [46]. Compared to other neoplastic disorders, the size of FNH is stable over time in the vast majority of cases. Case series of FNH showing that in the vast majority of cases the lesions remain stable, also indicate that the majority are asymptomatic, and that complications are extremely rare [44,47]. A slow incidental increase in size is not cause for concern in cases with a solid diagnosis. FNH is typically a solitary well-circumscribed, unencapsulated mass, showing a central fibrous scar, which contains dystrophic arterial vessels. Histologically, FNH is composed of benign-appearing hepatocytes arranged in nodules that are usually partially delineated by fibrous septa originating from the central scar. Several degrees of ductular proliferation and inflammatory cells may be observed in the fibrous septa. Besides the typical form, several atypical forms of FNH are recognized. FNH without a central scar is the most common of these; mostly absent in lesions <3 cm. FNH with significant steatosis are also recognized [48]. Molecular analysis identified upregulation of extracellular matrix genes associated with activation of the transforming growth factor beta (TGF-β) signaling pathway and overexpression of Wnt/β-catenin target genes, including *GLUL*, coding for glutamine synthase [49]. Such β-catenin activation without β-catenin activating mutations results in a typical map-like pattern of glutamine synthase (GS) overexpression in the periphery of the nodules close to the vessels [50]. This map-like pattern of GS expression is specific to FNH (Fig. 2A) and GS immunohistochemical staining is commonly used to help for pathological diagnosis in difficult cases [51].

Multiple FNH may be observed in specific clinical context, especially in patients with underlying vascular liver diseases, such as Budd-Chiari syndrome, obliterative portal venopathy and congenital disorders, including hereditary haemorrhagic telangiectasia, portal vein agenesis [52].

Imaging and diagnosis

Imaging features of FNH (Fig. 2B–E) resemble closely to pathologic findings. On US, FNH is usually slightly hypo- or isoechoic and very rarely hyperechoic. Sometimes the lesion is only detected by visualization of a pseudocapsule, which is due to compression of the surrounding liver tissue or vessels. Typically, on colour doppler, central arteries have a spoke-wheel pattern. Regardless of the imaging modality, FNH usually associates several findings: i) lesion homogeneity except the central scar, ii) slightly different from the adjacent liver on pre-contrast US, CT or MRI [53,54], iii) strong and homogeneous enhancement on

Please cite this article in press as: EASL Clinical Practice Guidelines on the management of benign liver tumours. J Hepatol (2016), http://dx.doi.org/10.1016/j.jhep.2016.04.001

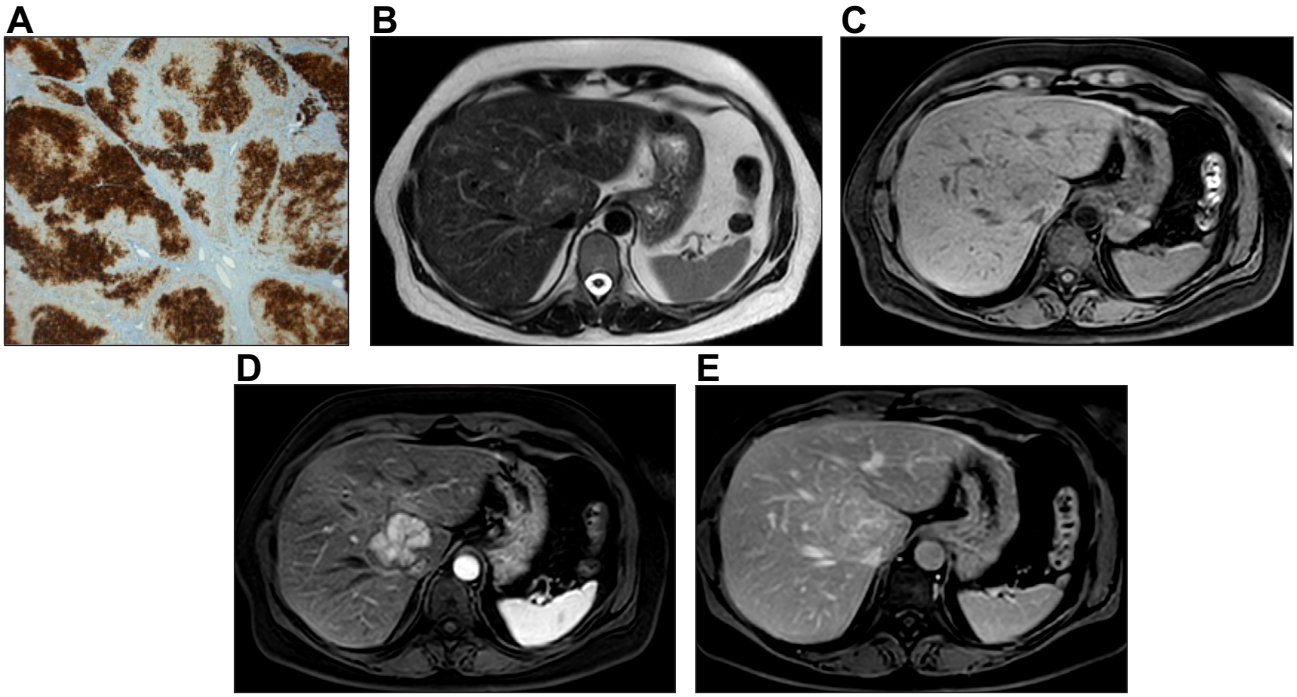

Fig. 2. A typical example of FNH. (A) Glutamine synthetase expression by immunostaining shows a "map-like" pattern in lesional hepatocytes. The positive hepatocellular areas are usually located around hepatic veins. (B and C) On the MRI, the lesion is barely seen on T2 and on T1. (D and E) On contrast enhanced images, the lesion shows strong and homogeneous enhancement on arterial phase and becomes iso-intense to the liver on portal venous phase. The central element is hyperintense on T2 and enhances on delayed phase imaging using extracellular contrast agents.

arterial phase CEUS, CT or MR with a central vascular supply, which becomes similar to adjacent liver on portal and delayed phases [36,55,56], iv) central scar best seen on MRI (hypointense on pre-contrast T1-weighted images, strongly hyperintense on T2-weighted images, and becoming hyperintense on delayed phase using extracellular MR contrast agents because of the accumulation of contrast material in the fibrous tissue [57,58]), and v) lack of capsule with often lobulated contours. The diagnosis of FNH is based on a combination of these imaging features but none of them is completely specific to FNH. On diffusion-weighted MRI, FNH may appear hyperintense on high b-values corresponding to mild diffusion restriction. Nevertheless, ADC values are usually close to that of the liver [59].

MRI has the highest sensitivity compared to ultrasound and CT and a specificity of almost 100% for the diagnosis of FNH. Yet, its sensitivity is lower (70–80%) especially in small FNHs where central scar is often missing. When all features are not met, combination of CEUS and MRI yields the highest diagnostic accuracy [60]. CEUS is more accurate than MRI in FNH smaller than 3 cm whereas the opposite is true in larger FNH [61,62].

Hepatobiliary MR contrast agents can be used to highlight the hepatocellular origin of the lesions. Most FNHs are iso-or hyperintense on hepatobiliary phase, some having rim-accentuated enhancement [63,64]. With hepatobiliary MR contrast agents, the sensitivity for diagnosing FNH has increased up to 90%. Based on the lesion intensity on hepatobiliary phase, the sensitivity and specificity to differentiate FNH from HCA with GD-BOPTA or gadoxetic acid MRI ranges 92–96.9% and 91–100%, respectively [63,65,66]. A recent meta-analysis confirmed the high diagnostic accuracy of hepatobiliary phase gadoxetic acid-enhanced MR imaging in the diagnosis of FNH *vs.* HCA; however, authors highlighted the fact that studies were few, heterogeneous, and at high risk for bias [67].

Among the atypias seen in FNH, one of the most common ones is the steatotic FNH, which can mimic HCA. Steatotic FNH seems to be more often observed in patients with liver steatosis. The diagnosis of steatotic FNH can be reached on imaging with very high specificity as long as all typical imaging findings are seen in the lesion [48]. Other atypical findings include strong hyperintensity on T2-weighted imaging, pseudocapsule that can mimic true capsule, and washout. In atypical cases on imaging, liver biopsy is indicated.

Management

There is insufficient evidence to support or refute elective surgery for FNH [68], but in the absence of symptoms and given the rarity of complications, a conservative approach is recommended. There is a poor correlation between FNH and symptoms and therefore even in the case of symptoms, treatment is rarely indicated. Treatment is only pursued in exceptional cases (e.g., pedunculated, expanding, exophytic) and resection is the treatment of choice. Non-surgical treatments should be reserved for those unfit for resection [69–73].

Where the diagnosis is firm and the individual asymptomatic, follow-up imaging is not required and the patients can be discharged, as summarized in Fig. 3. There is no indication for discontinuing OCPs and follow-up during pregnancy is not necessary. If the diagnosis of FNH is not firmly established on imaging, or the individual is symptomatic (relating to pain or compression), the patient should be referred to a benign liver MDT.

Please cite this article in press as: EASL Clinical Practice Guidelines on the management of benign liver tumours. J Hepatol (2016), http://dx.doi.org/10.1016/j.jhep.2016.04.001

Clinical Practice Guidelines

Focal nodular hyperplasia

- CEUS, CT, or MRI can diagnose FNH with nearly 100% specificity when typical imaging features are seen in combination (**evidence level II-2, grade of recommendation 1**)
- MRI has the highest diagnostic performance overall. The highest diagnostic accuracy by CEUS is achieved in FNH less than 3 cm (**evidence level II-2, grade of recommendation 1**)
- For a lesion typical of FNH follow-up is not necessary, unless there is underlying vascular liver disease (**evidence level III, grade of recommendation 2**)
- Treatment is not recommended (**evidence level II-3, grade of recommendation 2**)
- If imaging is atypical, or the patients is symptomatic, refer to a benign liver tumour MDT (**evidence level III, grade of recommendation 1**)

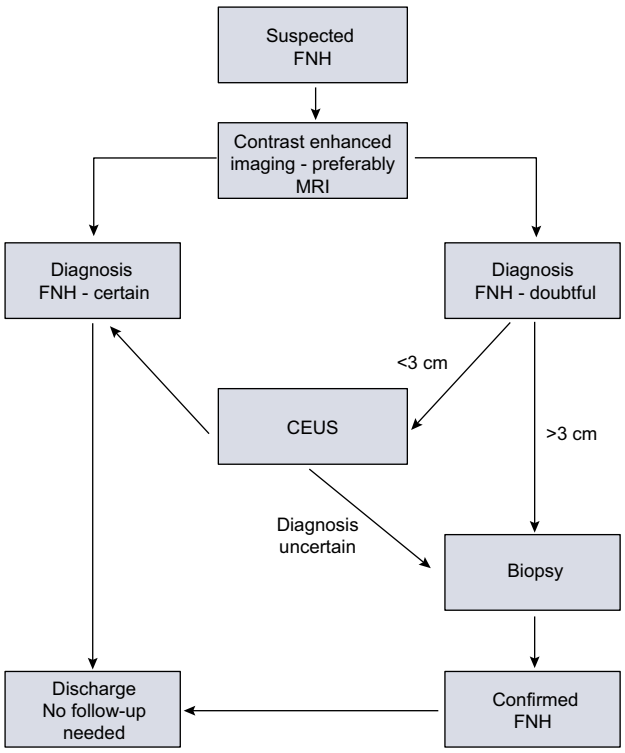

Fig. 3. Flow chart for the management of FNH; imaging modalities may include US, CEUS, CE-CT and CE-MRI. For large lesions (>3 cm), MRI sensitivity is very good. Different imaging modalities can be complementary and for lesions <3 cm, where sensitivity and certainty may be less, a second imaging modality such as CEUS is advised. If doubt remains after two imaging modalities, the patients should be referred to a specialist centre, where percutaneous or resection biopsy may be considered.

Hepatocellular adenoma

Epidemiology and etiology

Incidence and prevalence data for HCA are not well established, although the reported prevalence is between 0.001 and 0.004% [74,75]. HCA is approximately 10 times less common than FNH [75,76] and is frequently diagnosed in women age 35–40 years, with a reported female:male ratio of 10:1. Several studies have supported the potential role of sex hormones in the development of HCA. A 30–40 fold increase in the incidence of HCA has been assumed in long term users of OCPs [9,77]. The link between OCPs and increased risk of HCA in women was subsequently strengthened by the demonstration of a dose related risk ratio and the observation of occasional tumour regression upon drug withdrawal [78–80]. Notably, the incidence of HCA has increased in males [80] associated with the increase in the use of anabolic substances related to sport [81,82] or after the use of anabolic androgenic steroids by body builders [83]. HCA are associated with the use of androgenic steroid therapy for aplastic anemia [84] or paroxysmal nocturnal hemoglobinuria [85]. There are sporadic case reports of HCA in patients with elevated levels of endogenously produced androgens [86–88] or sex hormone imbalance (e.g., polycystic ovary, Klinefelter syndrome) [86,88]. The recent increase in the HCA prevalence is noticeably associated with the rising prevalence of obesity and the metabolic syndrome [89–93]. Rarer associations with implications for management include familial HCA associated with maturity onset diabetes type 3 (MODY3), iron overload related to β-thalassemia or hemochromatosis [94–97], McCune Albright syndrome [98], as well as type I, III and IV glycogen storage disease [99]. In glycogen storage diseases, the lifelong risk of HCA is particularly high. The tumours frequently appear during the second or third decade, with nearly half being classified as inflammatory adenoma (I-HCA). No HCA with inactivation of hepatocyte nuclear factor 1α (HNF-1α) (H-HCA) have been observed. Clinical guidelines recommend annual abdominal US between 0–10 years and biannual US beyond 10 years. Reduction in size and/or number has been observed following optimal metabolic control [100–103].

Pathophysiology, natural course and pathology

HCAs encompass various types of clonal benign hepatocellular proliferations including several molecular subgroups. These are associated with specific morphological features and significant risks of complications, mostly haemorrhage and malignant transformation [104,105]. HCA are usually solitary, sometimes pedunculated and of various size. The size ranges from several millimeters to 30 cm. Large subcapsular vessels are commonly found on macroscopic examination. On cut sections, the tumour is well-delineated, sometimes encapsulated, of fleshy appearance ranging in colour from white to brown. HCA may display heterogeneous areas of necrosis and/or haemorrhage. Histologically, HCA consist of a proliferation of benign hepatocytes arranged in a trabecular pattern. Small thin vessels are usually found throughout the tumour.

Unlike other benign liver lesions, HCA have the potential for haemorrhage and malignant transformation [106,107]. In nearly all cases of spontaneous rupture or haemorrhage the lesion is ⩾5 cm [108], although exophytic adenomas – even smaller ones – are associated with a higher risk [109]. Malignant

Please cite this article in press as: EASL Clinical Practice Guidelines on the management of benign liver tumours. J Hepatol (2016), http://dx.doi.org/10.1016/j.jhep.2016.04.001

transformation is relatively rare, but is more common in HCA with activating mutations in β-catenin [104,110] while HNF-1α mutated HCA rarely undergo malignant transformation [111,112]. The molecular classification of HCA is summarized in detail below. In practical terms, the course of HCA diagnosed in women is more often benign, while HCA diagnosed in men have a significantly higher incidence of malignant transformation [113], which at least partly reflects the differences in molecular subtypes in men and women [114].

HCA molecular classification

Based on genomic analysis, three main molecular subtypes of HCA have been clearly identified so far, with a fourth class presently uncharacterized.

1. *HCA inactivated for HNF-1α (H-HCA), accounting for 30 to 40% of HCA.*
   H-HCA are defined by inactivation of HNF-1α, a transcription factor involved in hepatocyte differentiation and metabolism control [104,115]. In H-HCA, HNF-1α mutations are somatic in most of cases, while germline mutations are observed in patients with adenomatosis and MODY3 diabetes, potentially in familial context [115–117]. Morphologically, H-HCAs are characterized by prominent steatosis [104], usually of marked intensity. However, steatosis may be mild in some H-HCA and significant in other subgroups of H-HCA, especially in inflammatory ones (I-HCA). The hallmark of H-HCA is the absence of expression in tumour hepatocytes of genes controlled by HNF-1α, among them, liver fatty acid binding protein (*LFABP*), which is in contrast highly expressed in non-tumour hepatocytes [104,118].
2. *Inflammatory Adenomas (I-HCA), accounting for 40 to 55% of HCA.*
   I-HCAs represent a heterogeneous subgroup of HCA regarding the variety of gene mutations, although all described mutations result in the activation of the JAK/STAT pathway [119]. Indeed, mutations of gp130 (*IL6ST*), *FRK*, *STAT3*, *GNAS* and *JAK1* have been identified in around 65%, 10%, 5%, 5% and 2% of I-HCA, respectively [98,120–122]. Almost all of these mutations are mutually exclusive. I-HCA are more often observed in patients with obesity and/or metabolic syndrome, as well as in the context of a high alcohol consumption. Systemic inflammatory syndrome, demonstrated by increased serum C-reactive protein (CRP) and fibrinogen levels, can regress following HCA removal. Morphologically, I-HCA, initially described as "telangiectatic form of FNH", further reclassified as "telangiectatic HCA", are characterized by the presence of clusters of small arteries surrounded by extracellular matrix and inflammatory infiltrates associated with foci of sinusoidal dilatation. By immunohistochemistry, tumour hepatocytes exhibit cytoplasmic expression of serum amyloid A (SAA) and CRP, two proteins of the acute phase of inflammation induced by STAT3 activation. CRP immunostaining appears to be more sensitive but less specific, since non-tumour hepatocytes may be positive in the adjacent normal liver counterpart. As previously mentioned, I-HCA may show some degree of steatosis and also features of β-HCA related to additional β-catenin mutations.
3. *β-catenin activated HCA (β-HCA), accounting for 10 to 20% of HCA.*
   β-HCA are defined by β-catenin activation within the tumours. Mutations of the β-catenin gene (*CTNNB1*) were initially localized at hot spots in exon 3, and more recently in exons 7 and 8 [104,122,123]. While β-catenin mutations are exclusive of HNF-1α mutations, they can be combined with a JAK/STAT activating mutation defining the subgroup of I-HCA; and up to 50% of β-HCA are also inflammatory [119,120,122]. β-HCA are over represented in males and display a higher risk of malignant transformation towards hepatocellular carcinoma (HCC). Morphologically, β-HCAs are characterized by the presence of cellular atypias, pseudoglandular formations and cholestasis. Tumoural hepatocytes show a specific immunophenotypical profile including diffuse, usually strong, GS positivity (a β-catenin target) as well as a nuclear expression of β-catenin. Although both markers have a very good specificity for β-catenin mutations, their sensitivity is insufficient, especially for β-catenin expression as a biomarker, since very few nuclei may be β-catenin positive [104]. More recently, exome sequencing analysis identified additional β-catenin mutations in exons 7 and 8 in HCA that were previously recognized as unclassified or inflammatory subgroups [122]. Those mutations were mutually exclusive from HNF-1α but also from β-catenin exon 3 mutations. Morphologically, these HCA may be unremarkable or show features of the I-HCA when they are associated with a JAK/STAT activation. They are not associated with an increased risk of malignant transformation. By immunohistochemistry, tumour hepatocytes display a faint patchy GS positivity without any β-catenin nuclear staining.
4. *Unclassified HCA, accounting for 5% to 10% of HCA.*
   A small subset of HCA do not display any specific morphological features nor do they have any of the gene mutations previously described.

HCA molecular classification has markedly contributed to the understanding of the oncogenic pathways involved in liver tumorigenesis. While the size of HCA, with the accepted clinically relevant size cut off of 5 cm correlating with the risk of complications – both haemorrhage and HCC development – the molecular subtyping is highly associated with the risk of malignant transformation into HCC. Among the different subgroups, β-HCAs exhibit the highest risk for malignancy, including those with dual β-catenin and inflammatory phenotype. As β-HCAs are enriched in male patients, this could at least in part explain the high risk of malignant transformation reported in men. Methods for the molecular analysis of HCA are not presently sensitive enough for widespread application. However, these molecular data have paved the way to the routine pathological assessment of HCA now including immunostaining with a combination of antibodies (LFABP, GS, β-catenin, SAA/CRP) which can subtype the majority of HCA. Whether the risk of haemorrhage or malignant transformation attributed to β-catenin activation in HCA is independent of the identified clinical risk factors (sex, size, rate of change) is presently unknown. There is no justification therefore to recommend histopathology or molecular subtyping of HCA as routine clinical practice. As evidence accumulates and methodologies improve with respect to risk and sensitivity, this may change.

Imaging and diagnosis

On imaging, HCA is no longer a unique entity and imaging features reflect the tumour subtypes. As the most striking pathologic features are the presence of fat or telangiectatic component, imaging should be fat sensitive and should use contrast agents

Please cite this article in press as: EASL Clinical Practice Guidelines on the management of benign liver tumours. J Hepatol (2016), http://dx.doi.org/10.1016/j.jhep.2016.04.001

Clinical Practice Guidelines

Table 2. The key features of HCA based on their molecular subtype.

		Typical features		
Genetic alterations	Pathology	IHC	Clinical	MRI**
HNF1-A mutations (30-40%)	Extensive steatosis	LFABP -ve	Adenomatosis, MODY3	Diffuse and homogenous signal dropout on opposed-phase T1
Inflammatory *Gp130* (65%), *GNAS* (5%), *STAT3* (5%), *FRK* (10%), *JAK1* (2%)	Inflammatory infiltration Clusters of vessels Sinusoidal dilatation	LFABP +ve SAA (± CRP) +ve	Obesity Alcohol consumption	Strong hyperintense on T2 and persistent enhancement on delayed phase using extracellular MR contrast agents
β-catenin mutations* exon 3 (5-10%)	Cell atypias Pseudoglandular formations Cholestasis	LFABP +ve GS +ve (diffuse) β-catenin nuclear +ve	Male Androgens use increased risk of HCC	No specific feature. Often heterogeneous on T1 and T2. No signal dropout on opposed-phase T1
β-catenin mutations exons 7-8 (5-10%)	No typical features or inflammatory phenotype	GS +ve (faint and patchy) β-catenin nuclear -ve		No specific Feature
Unclassified (5-10%)	None	LFABP +ve SAA/CRP -ve β-catenin nuclear -ve		No specific Feature

* 50% of β-catenin mutated HCA also display inflammatory phenotype.
** Using hepatospecific MR contrast agents and hepatobiliary sequences, most HCA appear hypointense. Yet, some are iso-or hyperintense on these sequences and seem to mainly correspond to inflammatory HCA. Gd-BOPA offers the possibility to evaluate both the delayed and the hepatobiliary phases.
CRP, C reactive protein; GS, glutamine synthase; IHC, immunohistochemistry; LFABP, liver fatty acid binding protein; SAA, serum amyloid A.

to look for dilated vascular spaces. CEUS, CT or MRI are able to detect the dilated vascular spaces. On CEUS, HCA usually shows homogeneous contrast enhancement in the arterial phase, typically with rapid complete centripetal filling. In the early portal venous phase, it usually becomes isoechoic or, more rarely, remains slightly hyperechoic. CEUS can differentiate HCA from FNH because of the absence of the central spoke-wheel pattern in HCA, but is not sufficiently accurate to subtype HCA [124].

HNF-1α inactivated HCAs are characterized by the presence of marked steatosis on pathology. They appear homogeneous on MRI and have a variable signal on T2-sequences: usually slightly hyperintense on non-fat suppressed sequence and iso-or hypointense on fat suppressed T2-weighted sequence. The striking finding is a diffuse and homogeneous signal dropout on chemical shift T1-weighted sequences [125,126]. They are usually moderately hypervascular and often show washout on portal and/or delayed phase using extracellular MR contrast agents. On high b-values diffusion-weighted MRI, they are iso-or moderately hyperintense. Using the diffuse and homogeneous signal dropout on chemical shift T1-weighted sequences, the sensitivity of MRI ranges from 87% to 91% and the specificity ranges from 89% to 100% for diagnosing HNF-1α inactivated HCA [125,126]. The two referenced series have included only hepatocellular adenomas with 50 and 44 cases, respectively.

Inflammatory HCAs are characterized on MRI by their telangiectatic features. They show a strong hyperintense signal on T2-weighted images (as strong as the signal of the spleen), which may be either diffuse or as a rim-like band in the periphery of the lesion and defines the atoll sign [111,125,126]. On T1-weighted sequences, lesion signal intensity is variably iso- to hyperintense. When present, hyperintensity persists on fat suppressed and opposed-phase sequences. They are markedly hypervascular and show persistent enhancement on delayed phase using extracellular MR contrast agents. Using the two striking imaging findings (strong hypersignal on T2-weighted MR images and the persistent enhancement on delayed phase), the sensitivity of MRI ranges from 85% to 88% and the specificity ranges from 88% to 100% for diagnosing inflammatory HCA with extracellular contrast agents [125,126]. Inflammatory HCAs may sometimes contain fat but the drop of signal intensity on chemical shift T1-weighted sequences is heterogeneous and moderate. Recent studies have shown that nearly half of the inflammatory HCAs are iso-or hyperintense on hepatobiliary MR phase using Gd-BOPTA or gadoxetic acid, mimicking that of FNH [112,127–129]. The study of Ba-Ssalamah *et al.* shows a sensitivity and specificity to subtype inflammatory HCA of 80.9% and 77.3% using gadoxetic acid, respectively, which are lower than reported with extracellular MR contrast agents.

The two other subtypes are less characteristic on imaging and cannot be differentiated from HCC. A β-catenin HCA can be diagnosed if the lesion is mainly heterogeneously hyperintense on T2- and hypointense on T1-weighted sequences, with a central scar but no signal loss on chemical shift sequences. On CE images, the lesions show arterial enhancement and can show either persistent or decreased signal intensity on portal venous phase [129]. In the study of Ba-Ssalamah *et al.*, five out of the six β-catenin HCAs displayed retention of the gadoxetic acid on hepatobiliary phase. Then, retention of gadoxetic acid has been observed in both inflammatory HCA and β-catenin HCA and was related to equivocal or increased expression of the biliary transporter OATP1B1/B3 [129].

As other hepatocellular tumours, unclassified HCA have strong arterial enhancement and they do not show any delayed enhancement after gadolinium injection. No characteristic imaging features have been proposed for unclassified HCA so far. Similar to other subtypes, haemorrhagic components have been also observed [107,121].

While MRI subtyping holds promise and is routinely practised in some specialised centres, future studies will define and validate the more widespread clinical usefulness of hepatobiliary MR contrast agents.

The key features of HCA based on their molecular subtype are summarized in Table 2.

Management

As HCAs have the potential for haemorrhage and malignant transformation, their diagnosis, baseline assessment and agreed follow-up plan (summarized in Fig. 4) should always involve a

Please cite this article in press as: EASL Clinical Practice Guidelines on the management of benign liver tumours. J Hepatol (2016), http://dx.doi.org/10.1016/j.jhep.2016.04.001

specialist benign liver tumour MDT. On baseline diagnostic imaging the size of an HCA is important to note, as is an exophytic characteristic if it is present, given the associations of haemorrhage with size ⩾5 cm and exophytic protrusion [108,109]. Irrespective of size, however, resection or curative treatment is recommended for all HCA diagnosed in men because of a significantly higher incidence of malignant transformation [113]. HCA in women that are less than 5 cm on the baseline scan rarely rupture [130] and malignant transformation less common. In women, lifestyle change is recommended and should include the discontinuation of OCPs and control of body weight.

For all presumed HCA, a reassessment with CE-MRI is advised after 6 months. HCA persistently greater than 5 cm, or increasing in size (⩾20% diameter – as per RECIST criteria for solid malignant tumours [131]) should be considered for resection or curative treatment – irrespective of their molecular or histological subtype – because of the risk of haemorrhage.

Biopsy may be considered within a benign liver tumour MDT to exclude malignancy. In the case of tissue availability obtained for diagnostic purpose, curative intervention is advised for the activated β-catenin mutated HCA, irrespective of size. HCA <5 cm of the HNF-1α subtype, or those that are either inflammatory or activated β-catenin negative on biopsy, can be managed conservatively. These lesions may still increase in size over time, despite lifestyle change. Follow-up imaging 6 monthly to establish growth patterns and monitor for malignant transformation is advisable. There is no robust data on the timeline to define stable disease. For lesions stable after 12 months, annual follow-up is acceptable. US is cost effective and may be preferred in well seen lesions. For lesions stable or reducing in size after 5 years, biannual imaging can be proposed [132]. HCA subtyping has not yet had an impact in general clinical practice, although may be used in some specialist centres, to support longer intervals between imaging follow-up, for example. Prospective validation of subtyping based on imaging characteristics will be necessary prior to recommendation of widespread implementation.

The recommended first line therapy is resection of larger (>5 cm) or growing lesions, aiming to remove the whole tumour and all risk of malignant transformation. Non-surgical modalities, such as embolization for larger lesions or ablation for smaller lesions can be pursued as an alternative to resection, but this would only be the treatment of choice in poor surgical candidates. For smaller indeterminate lesions, ablation without confirmation of diagnosis is not recommended. In these cases, biopsy should be considered. Small foci of haemorrhage within HCA are often observed and are not an indication for clinical intervention [89] (case series, evidence level 4). If clinically evident haemorrhage occurs, admission for close observation and CE-CT scan is appropriate. In cases of major haemorrhage, resuscitation with blood products and transfer to a centre where embolization can be performed to control active bleeding is appropriate [133]. Further investigation once stable should be pursued to exclude malignancy and secure appropriate follow-up.

HCA in a pregnant woman requires close follow-up using frequent US (every 6–12 weeks) to monitor size. Liasing with the obstetric team is essential if there is evidence of an increase in size of the lesion, with associated increased risk of rupture [134]. In the presence of adenomas <5 cm that are not exophytic or growing in size, there is no data supporting elective caesarian and vaginal delivery can be pursued. For growing lesions, embolization can be considered. Prior to 24 weeks, surgery may be preferred, especially for smaller resections located at the periphery of the liver anatomy, as the ionizing radiation exposure and the use of intravenous contrast agents associated with radiologically guided transarterial embolization may be harmful to the fetus [135].

Hepatocellular adenoma

- MRI is superior to all other imaging modalities and due to its intrinsic properties to detect fat and vascular spaces it offers an opportunity to subtype HCA up to 80% (**evidence level II-2, grade of recommendation 1**)
- The positive identification of HNF-1α HCA or inflammatory HCA is achievable with MRI with >90% specificity. By contrast, identification of β-catenin activated HCA and its distinction with unclassified HCA and hepatocellular carcinoma is not possible by any imaging technique (**evidence level II-2, grade of recommendation 1**)
- Treatment decisions are based on gender, size and pattern of progression (**evidence level III, grade of recommendation 2**)
- Upon HCA diagnosis, lifestyle changes such as discontinuation of OCP as well as weight loss should be advised (**evidence level II-2, grade of recommendation 1**)
- HCA resection is recommended irrespective of size in men and in any instance of proven β-catenin mutation (**evidence level II-3, grade of recommendation 2**)
- In women, a period of 6 months observation after lifestyle change is advised and resection is indicated for nodules equal or greater than 5 cm and those continuing to grow (**evidence level II-3, grade of recommendation 2**)
- In women, lesions less than 5 cm should be reassessed at 1 year, and annual imaging adopted thereafter (**evidence level III, grade of recommendation 2**)
- A bleeding HCA with haemodynamic instability should be embolized and residual viable lesion on follow-up imaging is an indication for resection (**evidence level III, grade of recommendation 2**)

How to approach the patient with multiple lesions

In retrospectively collected surgical series of patients, HCA presented as multinodular disease in up to a half all patients, was noted to be more frequent in OCP users and those with features of the metabolic syndrome, while being exceptionally rare in men [89,91,110,136]. In a proportion of patients with HCA, one or more lesions belonging to different classes, i.e., HCA, FNH or hemangiomata, are detected [90]. The term liver adenomatosis, that in the past meant the presence of more than 10 HCAs [89]

Please cite this article in press as: EASL Clinical Practice Guidelines on the management of benign liver tumours. J Hepatol (2016), http://dx.doi.org/10.1016/j.jhep.2016.04.001

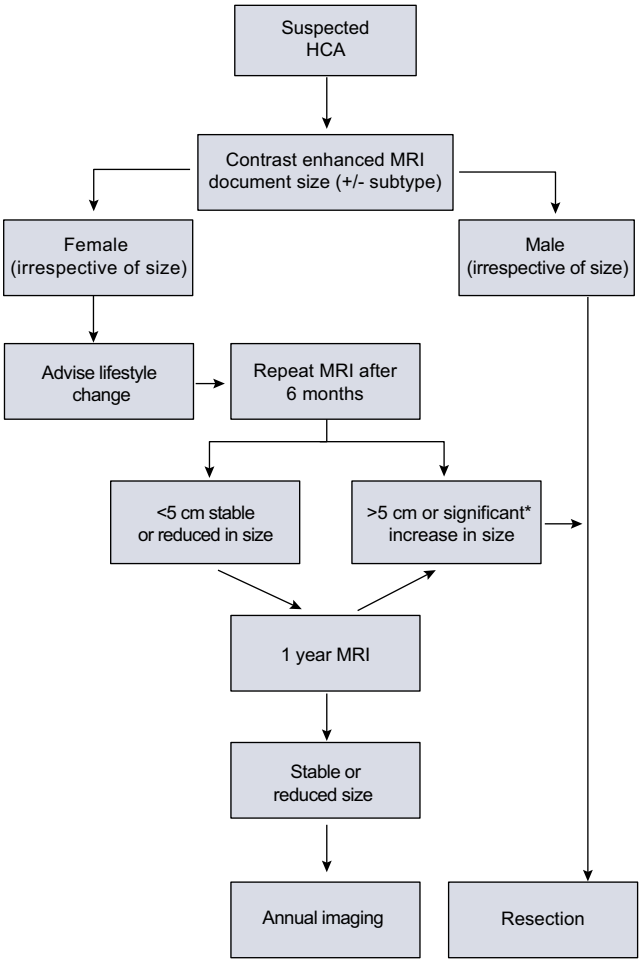

Fig. 4. Recommended management of a presumed HCA. Baseline MRI is necessary to help to confirm a diagnosis of HCA and characterize it. In men, resection is the treatment of choice. In women a period of 6 month observation, after lifestyle change, is appropriate. Resection is indicated in lesions persistently greater than 5 cm, or increasing in size. In smaller lesions, a conservative approach with interval imaging can be adopted. In specialist centres practising MRI subtyping, longer intervals between scans may be preferred for H-HCA. Biopsy is reserved for those cases where the diagnosis of HCA is uncertain on imaging and malignancy must be ruled out. *⩾20% diameter.

(case series, evidence level 4), has now been replaced with the term multiple HCAs – recognizing the fact that precise counting of HCA by imaging can be challenging. In patients with widespread HCAs involving both lobes, microscopic adenomatous foci escaping radiological detection have been found in up to 20% of the resected livers [89].

The clinical presentation and risk of bleeding and malignant transformation in patients with multiple HCAs do not differ from those in patients with a single HCA, being driven by the size of the largest nodule, rather than the number of nodules [89,110]. Regression of tumour burden has been reported to occur in up to a third of patients complying with lifestyle changes – such as withdrawal from OCPs or weight reduction, while progression of HCA is associated with obesity [110]. With these two things in mind, we recommend the management of patients with multiple HCA should be based on the size of the largest tumour.

Those individuals with unilobular disease can be treated with hepatic resection. For those with more widespread HCA, resection of the largest adenomas may be an option [137]. Because it often is impossible to resect all tumours in patients with multiple HCAs, liver transplantation has been proposed, but should only be considered in patients with more than 10 lesions and underlying liver disease [138].

Management of multiple lesions

- The management of patients with multiple HCA should be based on the size of the largest tumour (**evidence level III, grade of recommendation 2**)
- Hepatic resection might be considered in unilobular disease, and in those cases with more widespread HCA, resection of the largest adenomas may be an option (**evidence level III, grade of recommendation 2**)
- Liver transplantation is not recommended in multiple HCA, but might be considered in individuals with underlying liver disease (**evidence level III, grade of recommendation 2**)

Nodular regenerative hyperplasia

Nodular regenerative hyperplasia of the liver is a cause of non-cirrhotic portal hypertension. Although the histology is 'benign', the clinical course and management are distinct from the other benign lesions considered in this guideline. Nodular regenerative hyperplasia, its diagnostic features and its management have been reviewed elsewhere [139–143].

Conflict of interest

M. Colombo receives financial support from BMS and Gilead Science, acts as an advisor for Merck, Roche, Novartis, Bayer, BMS, Gilead Science, Tibotec, Vertex, Janssen Cilag, Achillion, Lundbeck, GSK, GenSpera, Abbve, AlfaWasserman, Jannerex and has given sponsored lectures for Tibotec, Roche, Novartis, Bayer, BMS, Gilead Science, Vertex, Merck, Janssen and Sanofi. Jessica Zucman-Rossi receives financial support from IntegraGen, acts as an advisor for IntegraGen, Astellas, Celgene, Blueprint and Pfizer and has given sponsored lectures for Bayer. A. Forner acts as an advisor and has given sponsored lectures for Bayer Healthcare. J. Ijzermans, V. Paradis, H. Reeves and V. Vilgrain declared that they do not have anything to disclose regarding funding or conflict of interest with respect to this manuscript.

Acknowledgements

We would like to thank the reviewers of this Clinical Practice Guideline for their time and critical reviewing: Carmen Ayuso, Peter Galle and Dominque Valla.

Please cite this article in press as: EASL Clinical Practice Guidelines on the management of benign liver tumours. J Hepatol (2016), http://dx.doi.org/10.1016/j.jhep.2016.04.001

References

[1] International Working P. Terminology of nodular hepatocellular lesions. Hepatology 1995;22:983–993.
[2] Guyatt GH, Oxman AD, Vist GE, Kunz R, Falck-Ytter Y, Alonso-Coello P, et al. GRADE: an emerging consensus on rating quality of evidence and strength of recommendations. BMJ 2008;336:924–926.
[3] Reddy KR, Schiff ER. Approach to a liver mass. Semin Liver Dis 1993;13:423–435.
[4] Bahirwani R, Reddy KR. Review article: the evaluation of solitary liver masses. Aliment Pharmacol Ther 2008;28:953–965.
[5] Rungsinaporn K, Phaisakamas T. Frequency of abnormalities detected by upper abdominal ultrasound. J Med Assoc Thai 2008;91:1072–1075.
[6] Horta G, Lopez M, Dotte A, Cordero J, Chesta C, Castro A, et al. Benign focal liver lesions detected by computed tomography: review of 1,184 examinations. Rev Med Chil 2015;143:197–202.
[7] Gandolfi L, Leo P, Solmi L, Vitelli E, Verros G, Colecchia A. Natural history of hepatic haemangiomas: clinical and ultrasound study. Gut 1991;32:677–680.
[8] Glinkova V, Shevah O, Boaz M, Levine A, Shirin H. Hepatic haemangiomas: possible association with female sex hormones. Gut 2004;53:1352–1355.
[9] Giannitrapani L, Soresi M, La Spada E, Cervello M, D'Alessandro N, Montalto G. Sex hormones and risk of liver tumor. Ann N Y Acad Sci 2006;1089:228–236.
[10] Hall GW. Kasabach-Merritt syndrome: pathogenesis and management. Br J Haematol 2001;112:851–862.
[11] O'Rafferty C, O'Regan GM, Irvine AD, Smith OP. Recent advances in the pathobiology and management of Kasabach-Merritt phenomenon. Br J Haematol 2015;171:38–51.
[12] Kim GE, Thung SN, Tsui WM, Ferrell LD. Hepatic cavernous hemangioma: underrecognized associated histologic features. Liver Int 2006;26:334–338.
[13] Wakasugi M, Ueshima S, Tei M, Tori M, Yoshida K, Tsujimoto M, et al. Multiple hepatic sclerosing hemangioma mimicking metastatic liver tumor successfully treated by laparoscopic surgery: report of a case. Int J Surg Case Rep 2015;8C:137–140.
[14] Quaia E, Bertolotto M, Dalla Palma L. Characterization of liver hemangiomas with pulse inversion harmonic imaging. Eur Radiol 2002;12:537–544.
[15] Itai Y, Ohtomo K, Furui S, Yamauchi T, Minami M, Yashiro N. Noninvasive diagnosis of small cavernous hemangioma of the liver: advantage of MRI. AJR Am J Roentgenol 1985;145:1195–1199.
[16] Stark DD, Felder RC, Wittenberg J, Saini S, Butch RJ, White ME, et al. Magnetic resonance imaging of cavernous hemangioma of the liver: tissue-specific characterization. AJR Am J Roentgenol 1985;145:213–222.
[17] Semelka RC, Brown ED, Ascher SM, Patt RH, Bagley AS, Li W, et al. Hepatic hemangiomas: a multi-institutional study of appearance on T2-weighted and serial gadolinium-enhanced gradient-echo MR images. Radiology 1994;192:401–406.
[18] Doo KW, Lee CH, Choi JW, Lee J, Kim KA, Park CM. "Pseudo washout" sign in high-flow hepatic hemangioma on gadoxetic acid contrast-enhanced MRI mimicking hypervascular tumor. AJR Am J Roentgenol 2009;193:W490–W496.
[19] Danet IM, Semelka RC, Braga L, Armao D, Woosley JT. Giant hemangioma of the liver: MR imaging characteristics in 24 patients. Magn Reson Imaging 2003;21:95–101.
[20] Coumbaras M, Wendum D, Monnier-Cholley L, Dahan H, Tubiana JM, Arrive L. CT and MR imaging features of pathologically proven atypical giant hemangiomas of the liver. AJR Am J Roentgenol 2002;179:1457–1463.
[21] Hanafusa K, Ohashi I, Himeno Y, Suzuki S, Shibuya H. Hepatic hemangioma: findings with two-phase CT. Radiology 1995;196:465–469.
[22] Gupta RT, Marin D, Boll DT, Husarik DB, Davis DE, Feuerlein S, et al. Hepatic hemangiomas: difference in enhancement pattern on 3T MR imaging with gadobenate dimeglumine versus gadoxetate disodium. Eur J Radiol 2012;81:2457–2462.
[23] Caldironi MW, Mazzucco M, Aldinio MT, Paccagnella D, Zani S, Pontini F, et al. Echo-guided fine-needle biopsy for the diagnosis of hepatic angioma. A report on 114 cases. Minerva Chir 1998;53:505–509.
[24] Hasan HY, Hinshaw JL, Borman EJ, Gegios A, Leverson G, Winslow ER. Assessing normal growth of hepatic hemangiomas during long-term follow-up. JAMA Surg 2014;149:1266–1271.
[25] Groeschl RT, Riggle KM, Quebbeman EJ, Christians KK, Turaga KK, Tsai S, et al. Hepatectomy for hemangioma; safe, but is it successful? Hepatogastroenterology 2014;61:2009–2013.
[26] Miura JT, Amini A, Schmocker R, Nichols S, Sukato D, Winslow ER, et al. Surgical management of hepatic hemangiomas: a multi-institutional experience. HPB (Oxford) 2014;16:924–928.
[27] Ebina Y, Hazama R, Nishimoto M, Tanimura K, Miyahara Y, Morizane M, et al. Resection of giant liver hemangioma in a pregnant woman with coagulopathy: case report and literature review. J Prenatal Med 2011;5:93–96.
[28] Giuliante F, Ardito F, Vellone M, Giordano M, Ranucci G, Piccoli M, et al. Reappraisal of surgical indications and approach for liver hemangioma: single-center experience on 74 patients. Am J Surg 2011;201:741–748.
[29] Ryan C, Price V, John P, Mahant S, Baruchel S, Brandao L, et al. Kasabach-Merritt phenomenon: a single centre experience. Eur J Haematol 2010;84:97–104.
[30] Wang P, Zhou W, Tao L, Zhao N, Chen XW. Clinical analysis of Kasabach-Merritt syndrome in 17 neonates. BMC Pediatr 2014;14:146.
[31] Tlougan BE, Lee MT, Drolet BA, Frieden IJ, Adams DM, Garzon MC. Medical management of tumors associated with Kasabach-Merritt phenomenon: an expert survey. J Pediatr Hematol Oncol 2013;35:618–622.
[32] Longeville JH, de la Hall P, Dolan P, Holt AW, Lillie PE, Williams JA, et al. Treatment of a giant haemangioma of the liver with Kasabach-Merritt syndrome by orthotopic liver transplant a case report. HPB Surg 1997;10:159–162.
[33] Toro A, Mahfouz AE, Ardiri A, Malaguarnera M, Malaguarnera G, Loria F, et al. What is changing in indications and treatment of hepatic hemangiomas. A review. Ann Hepatol 2014;13:327–339.
[34] Rubin RA, Mitchell DG. Evaluation of the solid hepatic mass. Med Clin North Am 1996;80:907–928.
[35] Marrero JA, Ahn J, Rajender Reddy KAmerical College of G. ACG clinical guideline: the diagnosis and management of focal liver lesions. Am J Gastroenterol 2014;109:1328–1347, quiz 1348.
[36] Brancatelli G, Federle MP, Grazioli L, Blachar A, Peterson MS, Thaete L. Focal nodular hyperplasia: CT findings with emphasis on multiphasic helical CT in 78 patients. Radiology 2001;219:61–68.
[37] Nguyen BN, Flejou JF, Terris B, Belghiti J, Degott C. Focal nodular hyperplasia of the liver: a comprehensive pathologic study of 305 lesions and recognition of new histologic forms. Am J Surg Pathol 1999;23:1441–1454.
[38] Vilgrain V, Uzan F, Brancatelli G, Federle MP, Zappa M, Menu Y. Prevalence of hepatic hemangioma in patients with focal nodular hyperplasia: MR imaging analysis. Radiology 2003;229:75–79.
[39] Laurent C, Trillaud H, Lepreux S, Balabaud C, Bioulac-Sage P. Association of adenoma and focal nodular hyperplasia: experience of a single French academic center. Comp Hepatol 2003;2:6.
[40] Bioulac-Sage P, Cubel G, Balabaud C, Zucman-Rossi J. Revisiting the pathology of resected benign hepatocellular nodules using new immunohistochemical markers. Semin Liver Dis 2011;31:91–103.
[41] Buscarini E, Danesino C, Plauchu H, de Fazio C, Olivieri C, Brambilla G, et al. High prevalence of hepatic focal nodular hyperplasia in subjects with hereditary hemorrhagic telangiectasia. Ultrasound Med Biol 2004;30:1089–1097.
[42] Bouyn CI, Leclere J, Raimondo G, Le Pointe HD, Couanet D, Valteau-Couanet D, et al. Hepatic focal nodular hyperplasia in children previously treated for a solid tumor. Incidence, risk factors, and outcome. Cancer 2003;97:3107–3113.
[43] Rifai K, Mix H, Krusche S, Potthoff A, Manns MP, Gebel MJ. No evidence of substantial growth progression or complications of large focal nodular hyperplasia during pregnancy. Scand J Gastroenterol 2013;48:88–92.
[44] D'Halluin V, Vilgrain V, Pelletier G, Rocher L, Belghiti J, Erlinger S, et al. Natural history of focal nodular hyperplasia. A retrospective study of 44 cases. Gastroenterol Clin Biol 2001;25:1008–1010.
[45] Ramirez-Fuentes C, Marti-Bonmati L, Torregrosa A, Del Val A, Martinez C. Variations in the size of focal nodular hyperplasia on magnetic resonance imaging. Radiologia 2013;55:499–504.
[46] Paradis V, Benzekri A, Dargere D, Bieche I, Laurendeau I, Vilgrain V, et al. Telangiectatic focal nodular hyperplasia: a variant of hepatocellular adenoma. Gastroenterology 2004;126:1323–1329.
[47] Perrakis A, Demir R, Muller V, Mulsow J, Aydin U, Alibek S, et al. Management of the focal nodular hyperplasia of the liver: evaluation of the surgical treatment comparing with observation only. Am J Surg 2012;204:689–696.
[48] Ronot M, Paradis V, Duran R, Kerbaol A, Vullierme MP, Belghiti J, et al. MR findings of steatotic focal nodular hyperplasia and comparison with other fatty tumours. Eur Radiol 2013;23:914–923.

Please cite this article in press as: EASL Clinical Practice Guidelines on the management of benign liver tumours. J Hepatol (2016), http://dx.doi.org/10.1016/j.jhep.2016.04.001

Clinical Practice Guidelines

[49] Rebouissou S, Couchy G, Libbrecht L, Balabaud C, Imbeaud S, Auffray C, et al. The beta-catenin pathway is activated in focal nodular hyperplasia but not in cirrhotic FNH-like nodules. J Hepatol 2008;49:61–71.
[50] Rebouissou S, Bioulac-Sage P, Zucman-Rossi J. Molecular pathogenesis of focal nodular hyperplasia and hepatocellular adenoma. J Hepatol 2008;48:163–170.
[51] Bioulac-Sage P, Laumonier H, Rullier A, Cubel G, Laurent C, Zucman-Rossi J, et al. Over-expression of glutamine synthetase in focal nodular hyperplasia: a novel easy diagnostic tool in surgical pathology. Liver Int 2009;29:459–465.
[52] Sempoux C, Paradis V, Komuta M, Wee A, Calderaro J, Balabaud C, et al. Hepatocellular nodules expressing markers of hepatocellular adenomas in Budd-Chiari syndrome and other rare hepatic vascular disorders. J Hepatol 2015;63:1173–1180.
[53] Vilgrain V, Flejou JF, Arrive L, Belghiti J, Najmark D, Menu Y, et al. Focal nodular hyperplasia of the liver: MR imaging and pathologic correlation in 37 patients. Radiology 1992;184:699–703.
[54] Buetow PC, Pantongrag-Brown L, Buck JL, Ros PR, Goodman ZD. Focal nodular hyperplasia of the liver: radiologic-pathologic correlation. Radiographics 1996;16:369–388.
[55] Kim MJ, Lim HK, Kim SH, Choi D, Lee WJ, Lee SJ, et al. Evaluation of hepatic focal nodular hyperplasia with contrast-enhanced gray scale harmonic sonography: initial experience. J Ultrasound Med 2004;23:297–305.
[56] Dietrich CF, Schuessler G, Trojan J, Fellbaum C, Ignee A. Differentiation of focal nodular hyperplasia and hepatocellular adenoma by contrast-enhanced ultrasound. Br J Radiol 2005;78:704–707.
[57] Mortele KJ, Praet M, Van Vlierberghe H, Kunnen M, Ros PR. CT and MR imaging findings in focal nodular hyperplasia of the liver: radiologic-pathologic correlation. AJR Am J Roentgenol 2000;175:687–692.
[58] Kehagias D, Moulopoulos L, Antoniou A, Hatziioannou A, Smyrniotis V, Trakadas S, et al. Focal nodular hyperplasia: imaging findings. Eur Radiol 2001;11:202–212.
[59] Agnello F, Ronot M, Valla DC, Sinkus R, Van Beers BE, Vilgrain V. High-b-value diffusion-weighted MR imaging of benign hepatocellular lesions: quantitative and qualitative analysis. Radiology 2012;262:511–519.
[60] Soussan M, Aube C, Bahrami S, Boursier J, Valla DC, Vilgrain V. Incidental focal solid liver lesions: diagnostic performance of contrast-enhanced ultrasound and MR imaging. Eur Radiol 2010;20:1715–1725.
[61] Bertin C, Egels S, Wagner M, Huynh-Charlier I, Vilgrain V, Lucidarme O. Contrast-enhanced ultrasound of focal nodular hyperplasia: a matter of size. Eur Radiol 2014;24:2561–2571.
[62] Roche V, Pigneur F, Tselikas L, Roux M, Baranes L, Djabbari M, et al. Differentiation of focal nodular hyperplasia from hepatocellular adenomas with low-mechanical-index contrast-enhanced sonography (CEUS): effect of size on diagnostic confidence. Eur Radiol 2015;25:186–195.
[63] Grazioli L, Morana G, Kirchin MA, Schneider G. Accurate differentiation of focal nodular hyperplasia from hepatic adenoma at gadobenate dimeglumine-enhanced MR imaging: prospective study. Radiology 2005;236:166–177.
[64] Grieser C, Steffen IG, Seehofer D, Kramme IB, Uktolseya R, Scheurig-Muenkler C, et al. Histopathologically confirmed focal nodular hyperplasia of the liver: gadoxetic acid-enhanced MRI characteristics. Magn Reson Imaging 2013;31:755–760.
[65] Grazioli L, Bondioni MP, Haradome H, Motosugi U, Tinti R, Frittoli B, et al. Hepatocellular adenoma and focal nodular hyperplasia: value of gadoxetic acid-enhanced MR imaging in differential diagnosis. Radiology 2012;262:520–529.
[66] Suh CH, Kim KW, Kim GY, Shin YM, Kim PN, Park SH. The diagnostic value of Gd-EOB-DTPA-MRI for the diagnosis of focal nodular hyperplasia: a systematic review and meta-analysis. Eur Radiol 2015;25:950–960.
[67] McInnes MD, Hibbert RM, Inacio JR, Schieda N. Focal nodular hyperplasia and hepatocellular adenoma: accuracy of gadoxetic acid-enhanced MR imaging-a systematic review. Radiology 2015;277:413–423.
[68] Colli A, Fraquelli M, Massironi S, Colucci A, Paggi S, Conte D. Elective surgery for benign liver tumours. Cochrane Database Syst Rev 2007: CD005164.
[69] Charny CK, Jarnagin WR, Schwartz LH, Frommeyer HS, DeMatteo RP, Fong Y, et al. Management of 155 patients with benign liver tumours. Br J Surg 2001;88:808–813.
[70] Amesur N, Hammond JS, Zajko AB, Geller DA, Gamblin TC. Management of unresectable symptomatic focal nodular hyperplasia with arterial embolization. J Vasc Interv Radiol 2009;20:543–547.
[71] Hedayati P, VanSonnenberg E, Shamos R, Gillespie T, McMullen W. Treatment of symptomatic focal nodular hyperplasia with percutaneous radiofrequency ablation. J Vasc Interv Radiol 2010;21:582–585.
[72] Terkivatan T, Hussain SM, Lameris JS, IJzermans JN. Transcatheter arterial embolization as a safe and effective treatment for focal nodular hyperplasia of the liver. Cardiovasc Intervent Radiol 2002;25:450–453.
[73] Birn J, Williams TR, Croteau D, Schwartz S, Sturza S, Getzen T. Transarterial embolization of symptomatic focal nodular hyperplasia. J Vasc Interv Radiol 2013;24:1647–1655.
[74] Bonder A, Afdhal N. Evaluation of liver lesions. Clin Liver Dis 2012;16:271–283.
[75] Karhunen PJ. Benign hepatic tumours and tumour like conditions in men. J Clin Pathol 1986;39:183–188.
[76] Cherqui D, Mathieu D, Zafrani ES, Dhumeaux D. Focal nodular hyperplasia and hepatocellular adenoma in women. Current data. Gastroenterol Clin Biol 1997;21:929–935.
[77] Rooks JB, Ory HW, Ishak KG, Strauss LT, Greenspan JR, Hill AP, et al. Epidemiology of hepatocellular adenoma. The role of oral contraceptive use. JAMA 1979;242:644–648.
[78] Edmondson HA, Henderson B, Benton B. Liver-cell adenomas associated with use of oral contraceptives. N Engl J Med 1976;294:470–472.
[79] Edmondson HA, Reynolds TB, Henderson B, Benton B. Regression of liver cell adenomas associated with oral contraceptives. Ann Intern Med 1977;86:180–182.
[80] Dokmak S, Belghiti J. Will weight loss become a future treatment of hepatocellular adenoma in obese patients? Liver Int 2015;35:2228–2232.
[81] Creagh TM, Rubin A, Evans DJ. Hepatic tumours induced by anabolic steroids in an athlete. J Clin Pathol 1988;41:441–443.
[82] Cohen C, Lawson D, DeRose PB. Sex and androgenic steroid receptor expression in hepatic adenomas. Hum Pathol 1998;29:1428–1432.
[83] Socas L, Zumbado M, Perez-Luzardo O, Ramos A, Perez C, Hernandez JR, et al. Hepatocellular adenomas associated with anabolic androgenic steroid abuse in bodybuilders: a report of two cases and a review of the literature. Br J Sports Med 2005;39 e27.
[84] Nakao A, Sakagami K, Nakata Y, Komazawa K, Amimoto T, Nakashima K, et al. Multiple hepatic adenomas caused by long-term administration of androgenic steroids for aplastic anemia in association with familial adenomatous polyposis. J Gastroenterol 2000;35:557–562.
[85] Hernandez-Nieto L, Bruguera M, Bombi J, Camacho L, Rozman C. Benign liver-cell adenoma associated with long-term administration of an androgenic-anabolic steroid (methandienone). Cancer 1977;40:1761–1764.
[86] Beuers U, Richter WO, Ritter MM, Wiebecke B, Schwandt P. Klinefelter's syndrome and liver adenoma. J Clin Gastroenterol 1991;13:214–216.
[87] Grange JD, Guechot J, Legendre C, Giboudeau J, Darnis F, Poupon R. Liver adenoma and focal nodular hyperplasia in a man with high endogenous sex steroids. Gastroenterology 1987;93:1409–1413.
[88] Triantafyllopoulou M, Whitington PF, Melin-Aldana H, Benya EC, Brickman W. Hepatic adenoma in an adolescent with elevated androgen levels. J Pediatr Gastroenterol Nutr 2007;44:640–642.
[89] Dokmak S, Paradis V, Vilgrain V, Sauvanet A, Farges O, Valla D, et al. A single-center surgical experience of 122 patients with single and multiple hepatocellular adenomas. Gastroenterology 2009;137:1698–1705.
[90] Paradis V, Champault A, Ronot M, Deschamps L, Valla DC, Vidaud D, et al. Telangiectatic adenoma: an entity associated with increased body mass index and inflammation. Hepatology 2007;46:140–146.
[91] Bunchorntavakul C, Bahirwani R, Drazek D, Soulen MC, Siegelman ES, Furth EE, et al. Clinical features and natural history of hepatocellular adenomas: the impact of obesity. Aliment Pharmacol Ther 2011;34:664–674.
[92] Bioulac-Sage P, Taouji S, Possenti L, Balabaud C. Hepatocellular adenoma subtypes: the impact of overweight and obesity. Liver Int 2012;32:1217–1221.
[93] Chang CY, Hernandez-Prera JC, Roayaie S, Schwartz M, Thung SN. Changing epidemiology of hepatocellular adenoma in the United States: review of the literature. Int J Hepatol 2013;2013 604860.
[94] Cannon 3rd RO, Dusheiko GM, Long Jr JA, Ishak KG, Kapur S, Anderson KD, et al. Hepatocellular adenoma in a young woman with beta-thalassemia and secondary iron overload. Gastroenterology 1981;81:352–355.
[95] Shuangshoti S, Thaicharoen A. Hepatocellular adenoma in a beta-thalassemic woman having secondary iron overload. J Med Assoc Thai 1994;77:108–112.
[96] Radhi JM, Loewy J. Hepatocellular adenomatosis associated with hereditary haemochromatosis. Postgrad Med J 2000;76:100–102.
[97] Ozenne V, Paradis V, Vullierme MP, Vilgrain V, Leblanc T, Belghiti J, et al. Liver tumours in patients with Fanconi anaemia: a report of three cases. Eur J Gastroenterol Hepatol 2008;20:1036–1039.
[98] Nault JC, Fabre M, Couchy G, Pilati C, Jeannot E, Tran Van Nhieu J, et al. GNAS-activating mutations define a rare subgroup of inflammatory liver tumors characterized by STAT3 activation. J Hepatol 2012;56:184–191.

Please cite this article in press as: EASL Clinical Practice Guidelines on the management of benign liver tumours. J Hepatol (2016), http://dx.doi.org/10.1016/j.jhep.2016.04.001

[99] Labrune P, Trioche P, Duvaltier I, Chevalier P, Odievre M. Hepatocellular adenomas in glycogen storage disease type I and III: a series of 43 patients and review of the literature. J Pediatr Gastroenterol Nutr 1997;24:276–279.
[100] Visser G, Rake JP, Labrune P, Leonard JV, Moses S, Ullrich K, et al. Consensus guidelines for management of glycogen storage disease type 1b - European Study on Glycogen Storage Disease Type 1. Eur J Pediatr 2002;161: S120–S123.
[101] Lee PJ. Glycogen storage disease type I: pathophysiology of liver adenomas. Eur J Pediatr 2002;161:S46–S49.
[102] Calderaro J, Labrune P, Morcrette G, Rebouissou S, Franco D, Prevot S, et al. Molecular characterization of hepatocellular adenomas developed in patients with glycogen storage disease type I. J Hepatol 2013;58:350–357.
[103] Sakellariou S, Al-Hussaini H, Scalori A, Samyn M, Heaton N, Portmann B, et al. Hepatocellular adenoma in glycogen storage disorder type I: a clinicopathological and molecular study. Histopathology 2012;60: E58–E65.
[104] Zucman-Rossi J, Jeannot E, Nhieu JT, Scoazec JY, Guettier C, Rebouissou S, et al. Genotype-phenotype correlation in hepatocellular adenoma: new classification and relationship with HCC. Hepatology 2006;43:515–524.
[105] Nault JC, Mallet M, Pilati C, Calderaro J, Bioulac-Sage P, Laurent C, et al. High frequency of telomerase reverse-transcriptase promoter somatic mutations in hepatocellular carcinoma and preneoplastic lesions. Nat Commun 2013;4:2218.
[106] Cho SW, Marsh JW, Steel J, Holloway SE, Heckman JT, Ochoa ER, et al. Surgical management of hepatocellular adenoma: take it or leave it? Ann Surg Oncol 2008;15:2795–2803.
[107] Ribeiro Junior MA, Chaib E, Saad WA, D'Albuquerque LA, Cecconello I. Surgical management of spontaneous ruptured hepatocellular adenoma. Clinics 2009;64:775–779.
[108] van Aalten SM, de Man RA, IJzermans JN, Terkivatan T. Systematic review of haemorrhage and rupture of hepatocellular adenomas. Br J Surg 2012;99: 911–916.
[109] Bieze M, Phoa SS, Verheij J, van Lienden KP, van Gulik TM. Risk factors for bleeding in hepatocellular adenoma. Br J Surg 2014;101:847–855.
[110] Bioulac-Sage P, Laumonier H, Couchy G, Le Bail B, Sa Cunha A, Rullier A, et al. Hepatocellular adenoma management and phenotypic classification: the Bordeaux experience. Hepatology 2009;50:481–489.
[111] van Aalten SM, Thomeer MG, Terkivatan T, Dwarkasing RS, Verheij J, de Man RA, et al. Hepatocellular adenomas: correlation of MR imaging findings with pathologic subtype classification. Radiology 2011;261: 172–181.
[112] Thomeer MG, Willemssen FE, Biermann KK, El Addouli H, de Man RA, Ijzermans JN, et al. MRI features of inflammatory hepatocellular adenomas on hepatocyte phase imaging with liver-specific contrast agents. J Magn Reson Imaging 2014;39:1259–1264.
[113] Farges O, Ferreira N, Dokmak S, Belghiti J, Bedossa P, Paradis V. Changing trends in malignant transformation of hepatocellular adenoma. Gut 2011;60:85–89.
[114] Liu TC, Vachharajani N, Chapman WC, Brunt EM. Noncirrhotic hepatocellular carcinoma: derivation from hepatocellular adenoma? Clinicopathologic analysis. Mod Pathol 2014;27:420–432.
[115] Bluteau O, Jeannot E, Bioulac-Sage P, Marques JM, Blanc JF, Bui H, et al. Bi-allelic inactivation of TCF1 in hepatic adenomas. Nat Genet 2002;32:312–315.
[116] Bacq Y, Jacquemin E, Balabaud C, Jeannot E, Scotto B, Branchereau S, et al. Familial liver adenomatosis associated with hepatocyte nuclear factor 1alpha inactivation. Gastroenterology 2003;125:1470–1475.
[117] Reznik Y, Dao T, Coutant R, Chiche L, Jeannot E, Clauin S, et al. Hepatocyte nuclear factor-1 alpha gene inactivation: cosegregation between liver adenomatosis and diabetes phenotypes in two maturity-onset diabetes of the young (MODY)3 families. J Clin Endocrinol Metab 2004;89:1476–1480.
[118] Rebouissou S, Imbeaud S, Balabaud C, Boulanger V, Bertrand-Michel J, Terce F, et al. HNF1alpha inactivation promotes lipogenesis in human hepatocellular adenoma independently of SREBP-1 and carbohydrate-response element-binding protein (ChREBP) activation. J Biol Chem 2007;282: 14437–14446.
[119] Nault JC, Bioulac-Sage P, Zucman-Rossi J. Hepatocellular benign tumors-from molecular classification to personalized clinical care. Gastroenterology 2013;144:888–902.
[120] Rebouissou S, Amessou M, Couchy G, Poussin K, Imbeaud S, Pilati C, et al. Frequent in-frame somatic deletions activate gp130 in inflammatory hepatocellular tumours. Nature 2009;457:200–204.
[121] Pilati C, Amessou M, Bihl MP, Balabaud C, Nhieu JT, Paradis V, et al. Somatic mutations activating STAT3 in human inflammatory hepatocellular adenomas. J Exp Med 2011;208:1359–1366.
[122] Pilati C, Letouze E, Nault JC, Imbeaud S, Boulai A, Calderaro J, et al. Genomic profiling of hepatocellular adenomas reveals recurrent FRK-activating mutations and the mechanisms of malignant transformation. Cancer Cell 2014;25:428–441.
[123] Chen YW, Jeng YM, Yeh SH, Chen PJ. P53 gene and Wnt signaling in benign neoplasms: beta-catenin mutations in hepatic adenoma but not in focal nodular hyperplasia. Hepatology 2002;36:927–935.
[124] D'Onofrio M, Crosara S, De Robertis R, Canestrini S, Mucelli RP. Contrast-enhanced ultrasound of focal liver lesions. AJR Am J Roentgenol 2015;205: W56–W66.
[125] Laumonier H, Bioulac-Sage P, Laurent C, Zucman-Rossi J, Balabaud C, Trillaud H. Hepatocellular adenomas: magnetic resonance imaging features as a function of molecular pathological classification. Hepatology 2008;48:808–818.
[126] Ronot M, Bahrami S, Calderaro J, Valla DC, Bedossa P, Belghiti J, et al. Hepatocellular adenomas: accuracy of magnetic resonance imaging and liver biopsy in subtype classification. Hepatology 2011;53:1182–1191.
[127] Agarwal S, Fuentes-Orrego JM, Arnason T, Misdraji J, Jhaveri KS, Harisinghani M, et al. Inflammatory hepatocellular adenomas can mimic focal nodular hyperplasia on gadoxetic acid-enhanced MRI. AJR Am J Roentgenol 2014;203:W408–W414.
[128] Roux M, Pigneur F, Calderaro J, Baranes L, Chiaradia M, Tselikas L, et al. Differentiation of focal nodular hyperplasia from hepatocellular adenoma: role of the quantitative analysis of gadobenate dimeglumine-enhanced hepatobiliary phase MRI. J Magn Reson Imaging 2015;42:1249–1258.
[129] Ba-Ssalamah A, Antunes C, Feier D, Bastati N, Hodge JC, Stift J, et al. Morphologic and Molecular Features of Hepatocellular Adenoma with Gadoxetic Acid-enhanced MR Imaging. Radiology 2015;277:104–113.
[130] van der Windt DJ, Kok NF, Hussain SM, Zondervan PE, Alwayn IP, de Man RA, et al. Case-orientated approach to the management of hepatocellular adenoma. Br J Surg 2006;93:1495–1502.
[131] Eisenhauer EA, Therasse P, Bogaerts J, Schwartz LH, Sargent D, Ford R, et al. New response evaluation criteria in solid tumours: revised RECIST guideline (version 1.1). Eur J Cancer 2009;45:228–247.
[132] Chun YS, Parker RJ, Inampudi S, Ehrenwald E, Batts KP, Burgart LJ, et al. Imaging surveillance of hypervascular liver lesions in non-cirrhotic patients. J Gastrointest Surg 2015;20:564–567.
[133] Huurman VA, Schaapherder AF. Management of ruptured hepatocellular adenoma. Dig Surg 2010;27:56–60.
[134] Noels JE, van Aalten SM, van der Windt DJ, Kok NF, de Man RA, Terkivatan T, et al. Management of hepatocellular adenoma during pregnancy. J Hepatol 2011;54:553–558.
[135] Lazarus E, Mayo-Smith WW, Mainiero MB, Spencer PK. CT in the evaluation of nontraumatic abdominal pain in pregnant women. Radiology 2007;244:784–790.
[136] Furlan A, van der Windt DJ, Nalesnik MA, Sholosh B, Ngan KK, Pealer KM, et al. Multiple hepatic adenomas associated with liver steatosis at CT and MRI: a case-control study. AJR Am J Roentgenol 2008;191:1430–1435.
[137] Vetelainen R, Erdogan D, de Graaf W, ten Kate F, Jansen PL, Gouma DJ, et al. Liver adenomatosis: re-evaluation of aetiology and management. Liver Int 2008;28:499–508.
[138] Wellen JR, Anderson CD, Doyle M, Shenoy S, Nadler M, Turmelle Y, et al. The role of liver transplantation for hepatic adenomatosis in the pediatric population: case report and review of the literature. Pediatr Transplant 2010;14:E16–E19.
[139] Arvanitaki M, Adler M. Nodular regenerative hyperplasia of the liver. A review of 14 cases. Hepatogastroenterology 2001;48:1425–1429.
[140] Ames JT, Federle MP, Chopra K. Distinguishing clinical and imaging features of nodular regenerative hyperplasia and large regenerative nodules of the liver. Clin Radiol 2009;64:1190–1195.
[141] Dachman AH, Ros PR, Goodman ZD, Olmsted WW, Ishak KG. Nodular regenerative hyperplasia of the liver: clinical and radiologic observations. AJR Am J Roentgenol 1987;148:717–722.
[142] Clouet M, Boulay I, Boudiaf M, Soyer P, Nemeth J, Kiselman R, et al. Imaging features of nodular regenerative hyperplasia of the liver mimicking hepatic metastases. Abdom Imaging 1999;24:258–261.
[143] Ghabril M, Vuppalanchi R. Drug-induced nodular regenerative hyperplasia. Semin Liver Dis 2014;34:240–245.

Please cite this article in press as: EASL Clinical Practice Guidelines on the management of benign liver tumours. J Hepatol (2016), http://dx.doi.org/10.1016/j.jhep.2016.04.001